

Relato de Caso

Oromandibular dystonia as a cause of temporomandibular disorder

Distonia oromandibular como causa de disfunção temporomandibular

Carolina Orge¹, Juliana Melo¹, Irenio Gomes¹, Ailton Melo¹**ABSTRACT**

Temporomandibular disorders (TMD) can have multiple etiologies, including oromandibular dystonia (OMD). However, in a few cases, the OMD can evolve from cervical dystonia (CD), leading to severe bone degeneration.

The purpose of this case report of a 64-year-old woman presenting to the Outpatient Neurology Clinic of the Federal University of Bahia is to illustrate the development of oromandibular dystonia with temporomandibular joint (TMJ) dysfunction after 10 years of cervical dystonia. Clinical examination showed bone degeneration of the mandibular ramus and right TMJ click, a prevalent sound in patients with temporomandibular disorders when they open their mouths or chew. After onabotulinum toxin type A injections in the right lateral pterygoid muscle, the patient improved in swallowing and pain.

This case highlights the importance of close follow-up of cervical dystonia patients to identify new dystonic muscles. In our patient, lateral pterygoid muscle involvement was followed by several comorbidities, such as dysphagia and jawbone abnormalities.

Keywords: BoNT-A, onabotulinum toxin-A, TMD, temporomandibular disorders, temporomandibular joint degeneration, TMJ, temporomandibular joint, oromandibular dystonia.

RESUMO

Os distúrbios temporomandibulares (DTM) podem ter múltiplas etiologias, incluindo a distonia oromandibular (DO). No entanto, em raros casos, a DO pode evoluir a partir da distonia cervical (DC) e raramente pode levar a degeneração óssea.

O objetivo deste relato de caso de uma mulher de 64 anos atendida no Ambulatório de Neurologia da Universidade Federal da Bahia é ilustrar o desenvolvimento de distonia oromandibular com disfunção da articulação temporomandibular (ATM) após 10 anos de distonia cervical. O exame clínico mostrou degeneração óssea do ramo mandibular e clique na ATM direita, um som prevalente em pacientes com distúrbios temporomandibulares quando abrem a boca ou mastigam. Após injeções de toxina botulínica tipo A no músculo pterigoideo lateral direito, a paciente apresentou melhora na deglutição e na dor.

Este caso destaca a importância do acompanhamento próximo de pacientes com distonia cervical para identificar novos músculos distônicos. Em nossa paciente, o envolvimento do músculo pterigoideo lateral foi seguido por várias comorbidades, como disfagia e anormalidades ósseas da mandíbula.

Palavras-chave: BoNT-A, onabotulinum toxin-A, DTM, distúrbios temporomandibulares, degeneração da articulação temporomandibular, ATM, articulação temporomandibular, distonia oromandibular.

¹Program in Medicine and Health, School of Medicine, Federal University of Bahia, Salvador, Brazil

Conflict of interests: The authors have no conflicts of interest to declare.

Funding: The authors didn't receive any grant or honorary regarding this paper.

Carolina Orge receives scholarship from Coordination for the Training of Higher Education Personnel - CAPES - Brazilian Ministry of Education. The funder had no role in study design, data collection and analysis, decision to publish, or preparation of the manuscript.

Corresponding author: Ailton Melo

E-mail address: asm@ufba.br

INTRODUCTION

Temporomandibular disorders (TMD) are a musculoskeletal group of conditions secondary to a variety of etiologies related to dysfunction of the masticatory muscles and/or temporomandibular joints (TMJ)¹. Many diseases are associated with TMDs, and the symptoms are usually associated with mispositioning of the TMJ disc or systemic or muscle diseases. TMJ click is a prevalent sound in patients with the temporomandibular disorder when they open their mouths or chew. Oromandibular dystonia is a rare involuntary movement disorder characterized by repetitive or continuous contraction of the masticatory, tongue, or facial muscles, mainly manifested by eye blinking, jaw closing, jaw opening, jaw deviation, or a combination of these². The treatment of choice for OMD is botulinum neurotoxin (BoNT) injections in the affected muscles to alleviate pain and reduce the deviation of the mandible³. This paper describes a case of painful subluxation of TMJ and its evolution.

CASE PRESENTATION

This paper was approved by the Ethics and Research Committee of Federal University Hospital of Bahia/Brazil, under number 68984823.4.0000.0049.

A 64-year-old woman was referred to the neurologic clinic of the Federal University of Bahia in 2010 with cervical pain and mild torticollis and laterocollis to the right side. According to the patient, this condition had been present for at least two years and was increased with stress. The patient gave a history of asthma with irregular use of beclomethasone. No previous treatment to dizziness, neurological or psychiatry disorders and she denied chronic use of other medications.

On examination she showed mandibular lateral deviation associated with condyle subluxation during mouth opening. Since then, chemical block with onabotulinum toxin-A was performed each 5 to 6 months in the left ECM and middle and posterior scalenus muscles with improvement of pain and muscle contraction. In December 2021, after 14 months with no medical consultation, she returned and complained of progressive difficulty to

swallow, adopting flexed posture of head to feed only semiliquid food. Her neurological examination showed anterocollis with mild torticollis and head inclination to right, as well as maintained opened mouth. No other neurological problem. When asked to eat a cookie she showed sialorrhea, pain in the temporal region of head, click sound and dislocation in the right temporomandibular joint (TMJ). CT-Scan of her TMJ showed bone sclerosis of the right mandibular ramus associated with thin joint space and flattening of articular surfaces (Figure 1). BoNT-A injection was performed in her middle and posterior scalenus and both ECM as well as right lateral pterygoid muscle under guided EMG. One week later she reported improvement of pain and she could close her mouth, speak and she began to eat regular diet (Figure 2). She is now under multidisciplinary rehabilitation with special care to improve swallow and TMJ protection.

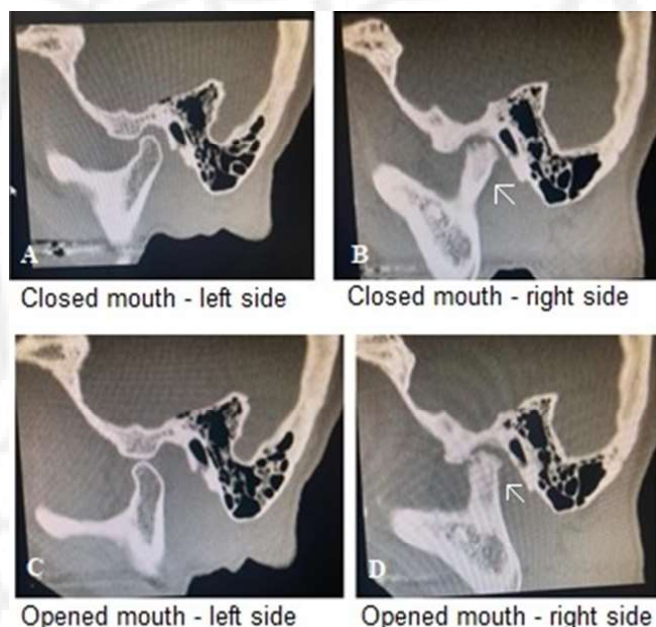

Figure 1. Computerized tomography of temporomandibular joints. **A** and **C** shows normal temporomandibular joints. **B**. White arrow indicating sclerosis and degeneration of right condyles and mandibular ramus. **D**. White arrow showing the lack of condyle translation during opened mouth. **B** and **D** shows degeneration and narrowing of the right mandibular fossa.

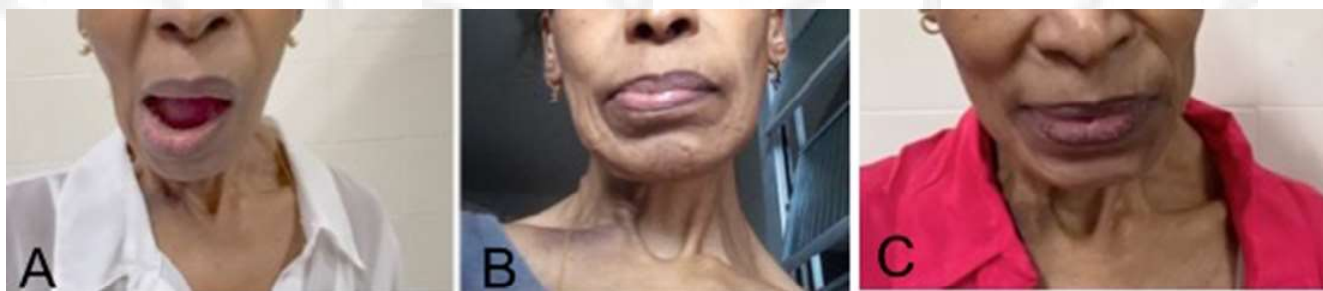


Figure 2. **A.** Before BoNT-A. **B.** After 30 days of BoNT-A. **C.** After 4 months of BoNT-A.

DISCUSSION

Oromandibular dystonia associated to TMJ subluxation is one of the most troublesome issue to health professionals, requiring multidisciplinary approach to conduct the case. In this report a previous history of periodic cervical injection of BoNT-A to treat cervical dystonia was interrupted after the beginning of coronavirus pandemic, and when the patient returned to neurological evaluation, she also had oromandibular dystonia, mandibular subluxation and bone degeneration. The first problem to be discussed is the pattern changing of dystonia with recruiting of the right lateral pterygoid muscle after approximately 10 years. In a previous report, Münchaut et al. observed that 9 from 17 patients with cervical dystonia presented different cervical muscles activation pattern after EMG and video recording⁴. As has been observed, neck muscle activation patterns can spontaneously change in CD patients, implying an inherent variability of the underlying central motor program in some dystonic patients. Probably BoNT-A help to interfere in the CNS programming of the movement, interfering in the proprioceptive activity of the spindle muscles⁵. In this paper, our patient had a facial muscle involvement after 10 years of only cervical dystonia, which, as far as we concern, has not been described previously. Another point to discuss is the bone degeneration associated to the subluxation affecting the right mandibular ramus and mandibular fossa. The observed sclerosis is probably related to continuous attrition of the right mandibular ramus resulting to deformity of the TMJ complex. If no treatment was undertaken, our patient would continuously modify the bone microarchitecture which consequently would increase the bone fragility and risk of fractures. It has to be noted that her age is a risk factor to osteoporosis which increases the probability of fractures. In addition, recurrent dislocation can damage joint capsule and ligaments as well as compromise the external meatus acoustic resulting in listening problems. The closer proximity between the TMJ disk and the mandibular nerve could be one of the causes of neuropathic pain in these patients⁶. In our case, after BoNT-A injection there was improvement of pain and swallowing and the patient is now under multi-disciplinary rehabilitation to prevent recurrent dislocation and additional problems.

CONCLUSION

The possibility of OMD should be considered in patients diagnosed with cervical dystonia who evolve with oromandibular pain, dysphagia, or speech difficulty. In our case, the diagnosis was delayed due to the COVID pandemic. Healthcare professionals should closely monitor OMD patients to avoid TMJ degeneration, which can lead to other comorbidities, increasing costs, and suffering.

REFERENCES

1. Ohrbach R, Bair E, Fillingim RB, Gonzalez Y, Gordon SM, Lim PF, Ribeiro-Dasilva M, Diatchenko L, Dubner R, Greenspan JD, Knott C, Maixner W, Smith SB, Slade GD. Clinical orofacial characteristics associated with risk of first-onset TMD: the OPPERA prospective cohort study. *J Pain* 2013;14:T33-50.
2. Raoofi S, Khorshidi H, Najafi M. Etiology, diagnosis and management of oromandibular dystonia: an update for stomatologist. *J Dent (Shiraz)* 2017;18:73-81.
3. Mendes RA, Upton LG. Management of dystonia of the lateral pterygoid muscle with botulinum toxin A. *Br J Oral Maxillofac Surg* 2009;47:481-3.
4. Münchaut A, Filipovic SR, Oester-Barkey A, Quinn NP, Rothwell JC, Bhatia KP. Spontaneously changing muscular activation pattern in patients with cervical dystonia. *Mov Disord*. 2001;16(6):1091-1097. doi:10.1002/mds.1236
5. Rosales RL, Dressler D. On muscle spindles, dystonia and botulinum toxin. *Eur J Neurol*. 2010;17 Suppl 1:71-80. doi:10.1111/j.1468-1331.2010.03056.x
6. Pedullà E, Meli GA, Garufi A, Mandalà ML, Blandino A, Cascone P. Neuropathic pain in temporomandibular joint disorders: case-control analysis by MR imaging. *AJNR Am J Neuroradiol* 2009;30(7):1414-1418.